

The Thoracic Aorta

J. Matthew Toole MD
RSFPP Cardiac Surgery

Thoracic Aortic Anatomy

9/18/22, 3:00 PM

Aortic root

- valve
- sinuses
- coronary ostia
- sinotubular junction (STJ)

Ascending aorta

- STJ-Innominate artery

Aortic arch

- Innominate
- left carotid
- left subclavian

Descending thoracic aorta

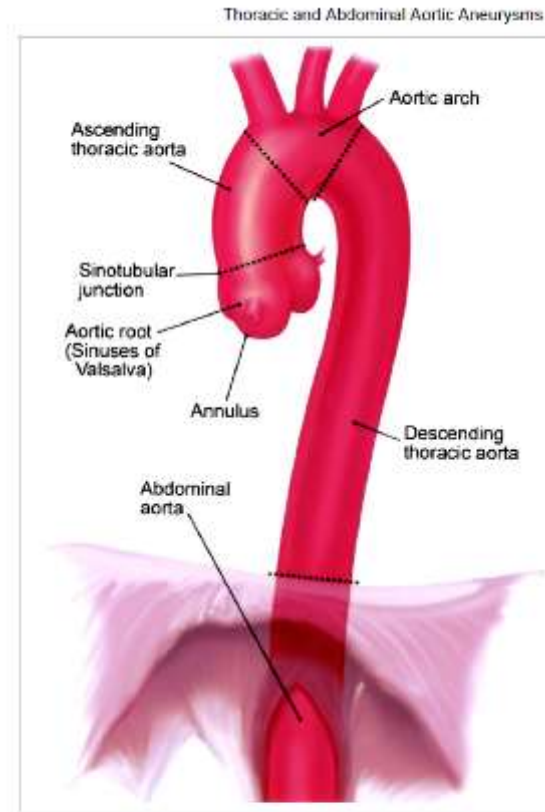
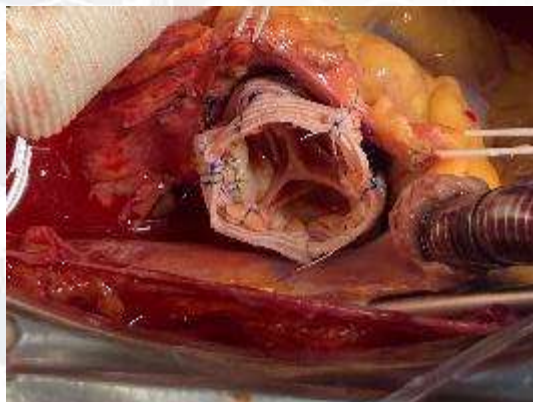

Figure 1. Anatomy of thoracic and proximal abdominal aorta. (©Massachusetts General Hospital Thoracic Aortic Center. Used with permission.)

Aortic Root Replacement



9/18/22, 3:00 PM



Thoracic and Abdominal Aortic Aneurysms

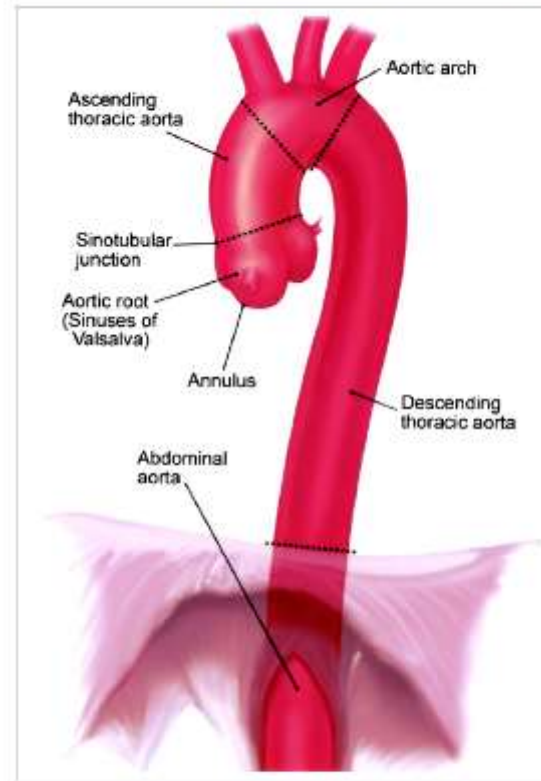
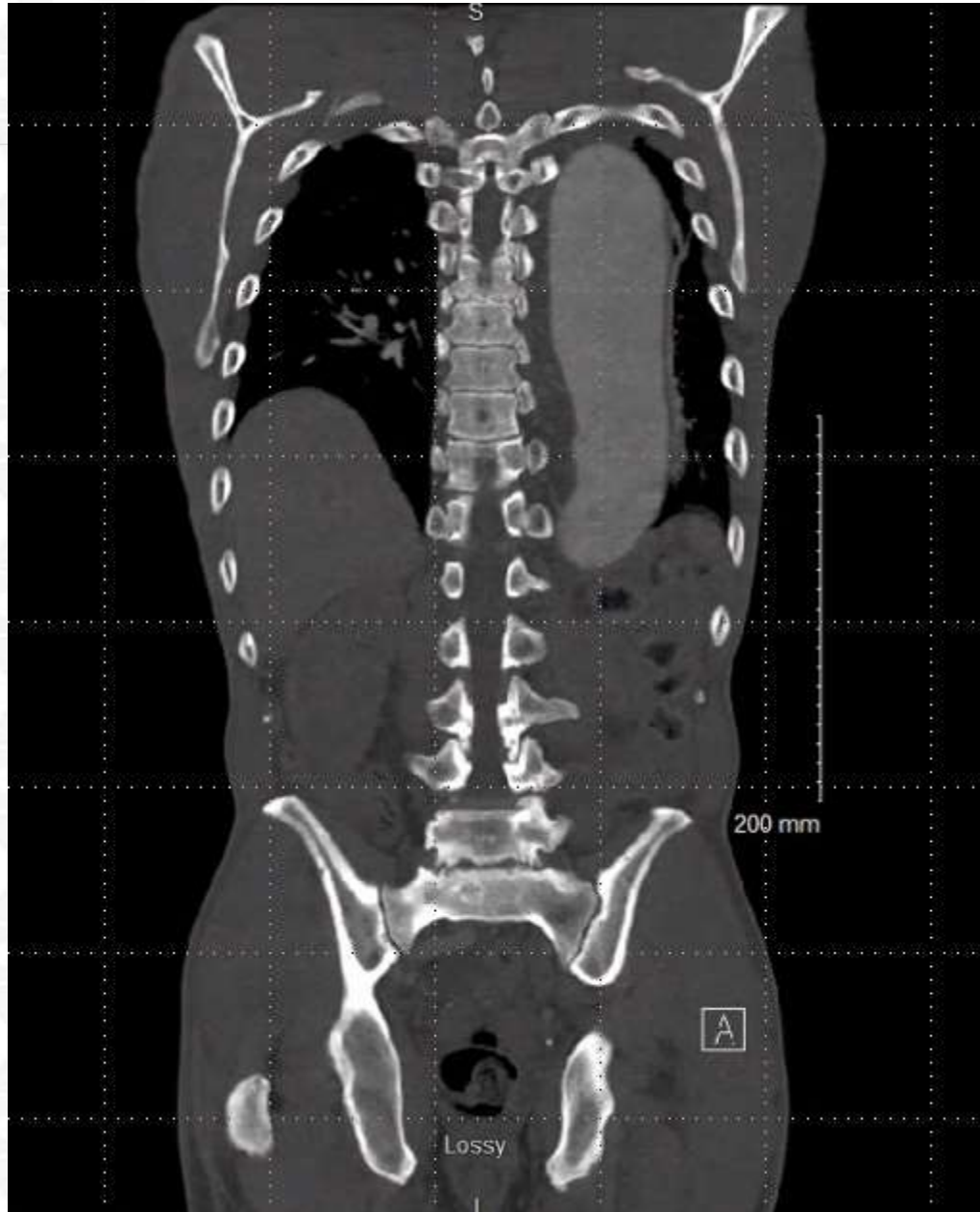
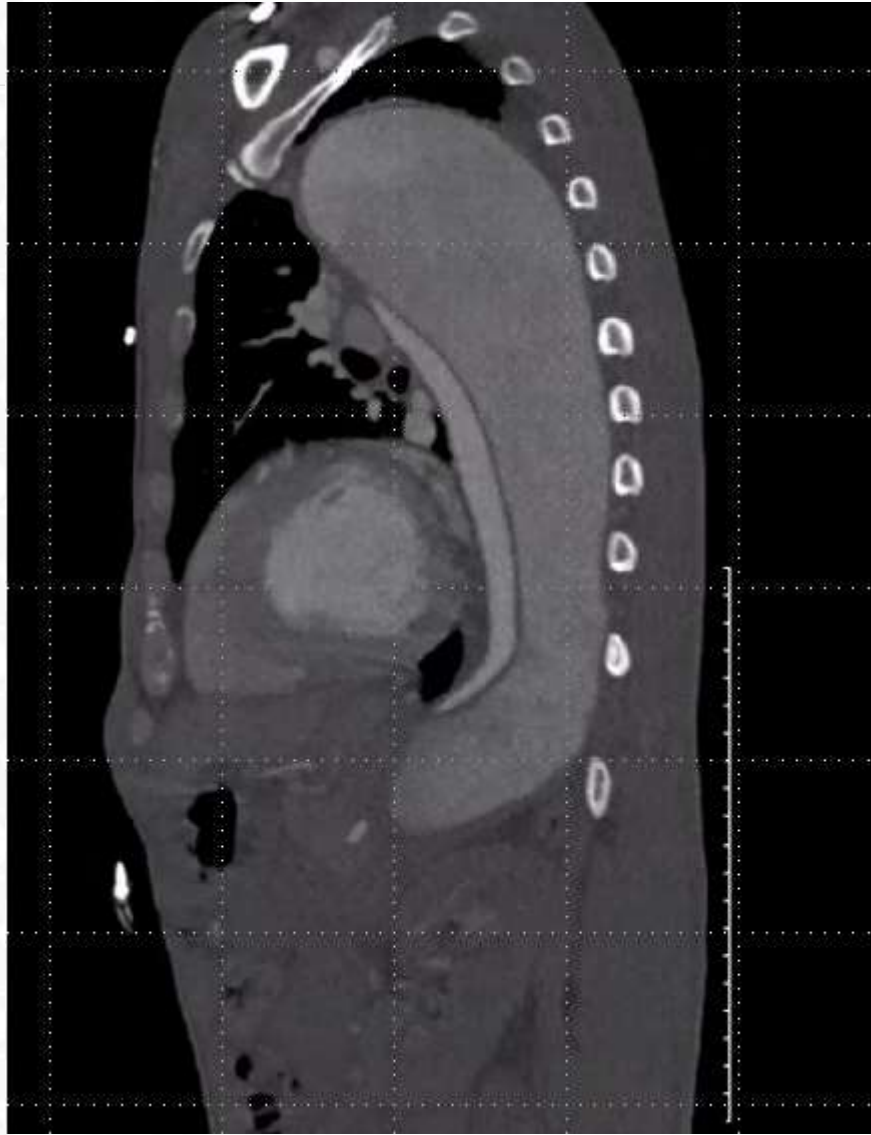


Figure 1. Anatomy of thoracic and proximal abdominal aorta. (©Massachusetts General Hospital Thoracic Aortic Center. Used with permission.)

Case presentation

- ES is a 55-year-old male who presented with 6-month history of left sided chest/back pain which had been acutely worse for 12 hours.
- Homeless
 - Poor medical compliance
 - Social
 - Economic
 - Unreliable follow up
 - Communication
 - Transportation





PHILIPS

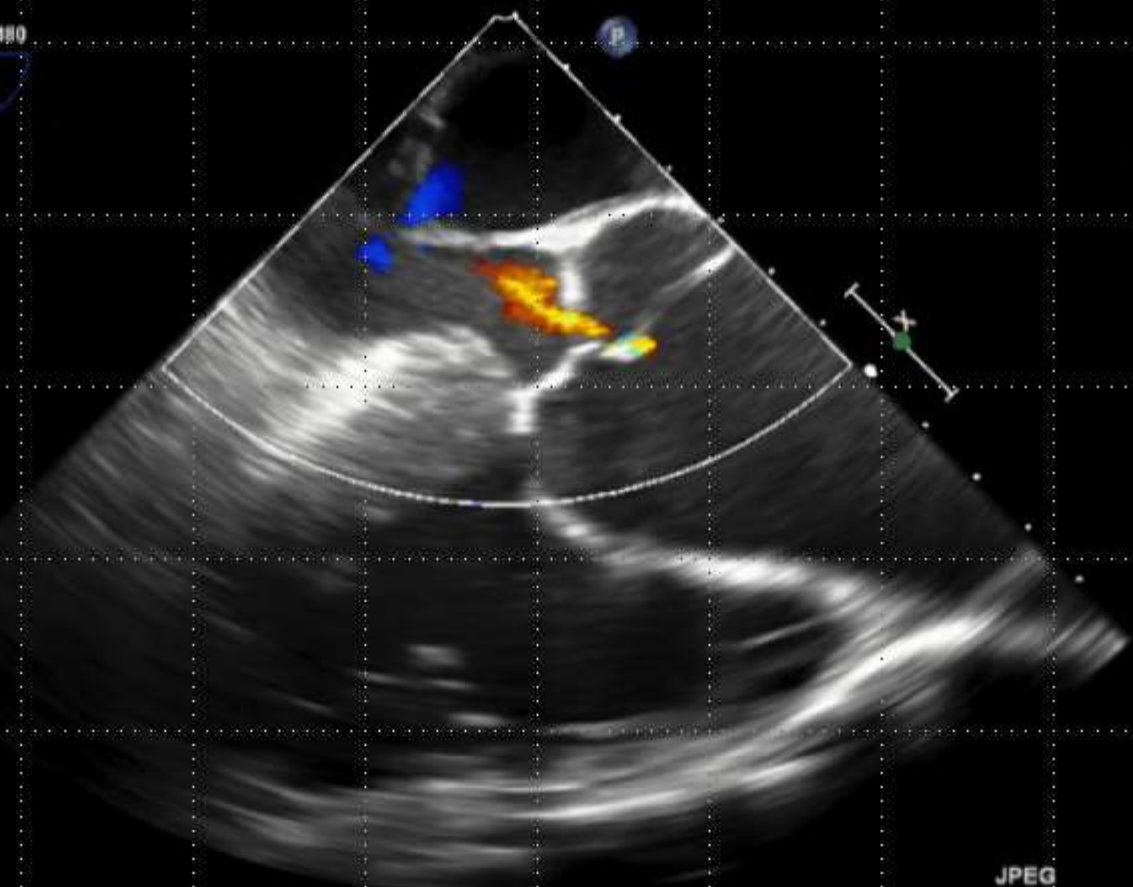

TIS0.4 MI 0.8

X7-2t/TEE

FR 11Hz
12cm

2D
70%
C 52
P Off
Gen

CF
57%
4.4MHz
WF High
Med



JPEG

PAT T: 37.0C
TEE T: 38.3C

*** bpm

Operative decision making

-Descending first

- Prioritizes lethal segment
- TEVAR not an option
- Requires hypothermic circulatory arrest(as will the ascending)
- Difficult exposure

-Aortic root and ascending first

- Addresses aortic root, ascending and arch directly and allows for TEVAR of descending thoracic type B dissection
- Hypothermic circulatory arrest required once
- Root replacement options

9/18/22, 3:00 PM

Thoracic and Abdominal Aortic Aneurysms

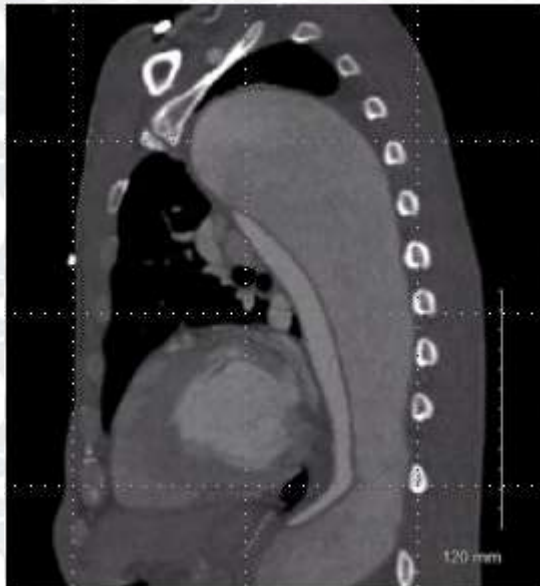
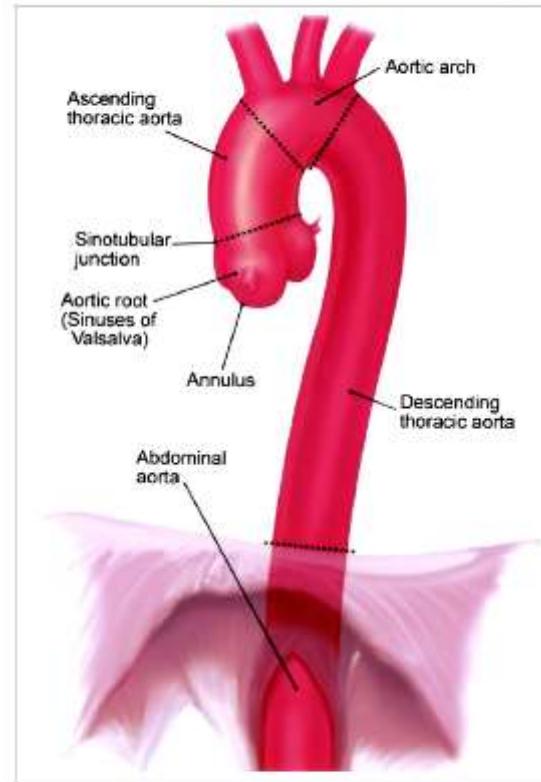


Figure 1. Anatomy of thoracic and proximal abdominal aorta. (©Massachusetts General Hospital Thoracic Aortic Center. Used with permission.)

Operative plan

Aortic root replacement

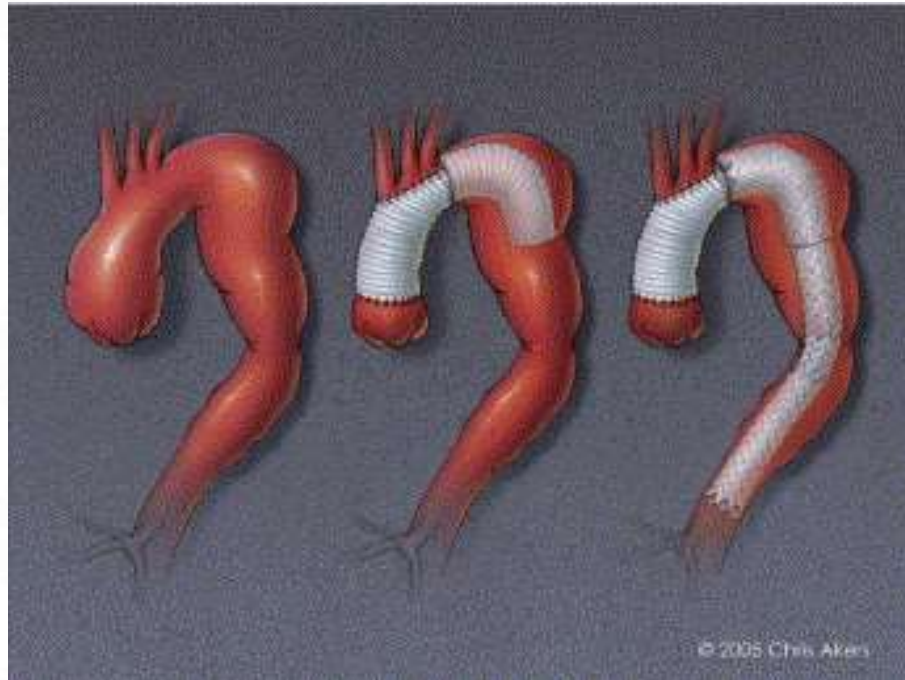
- Bioprosthetic valve conduit
- Mechanical valve conduit
- Valve sparing root replacement



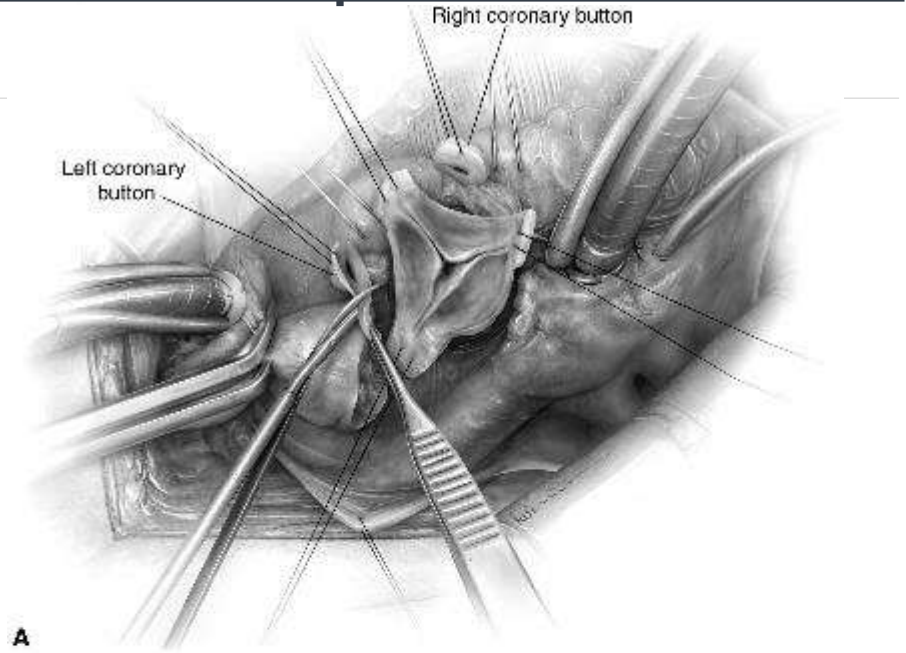
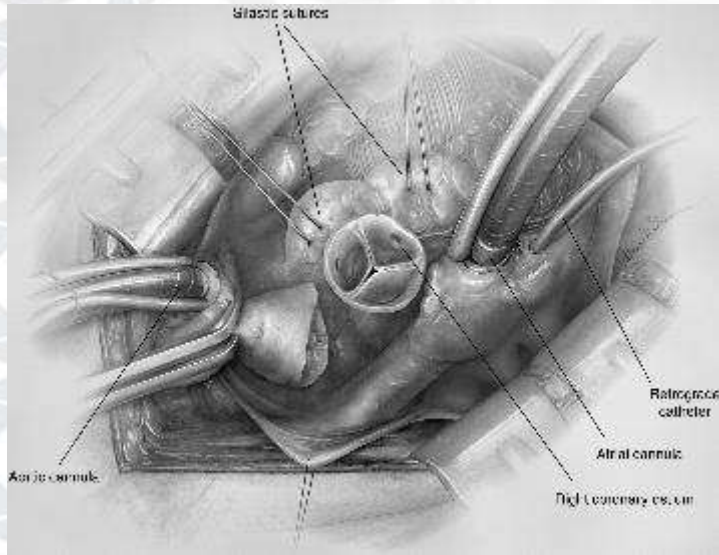
Ascending and aortic arch replacement with elephant trunk



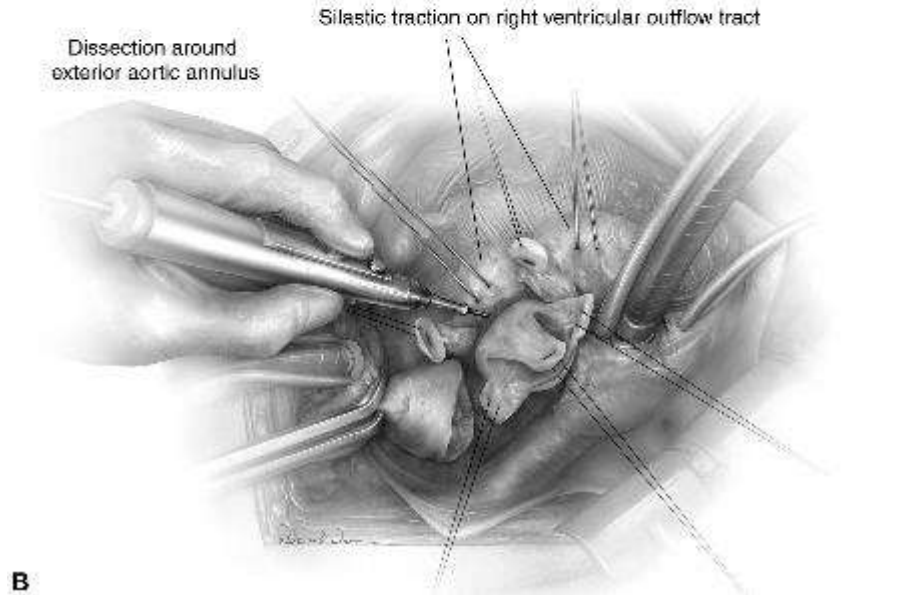
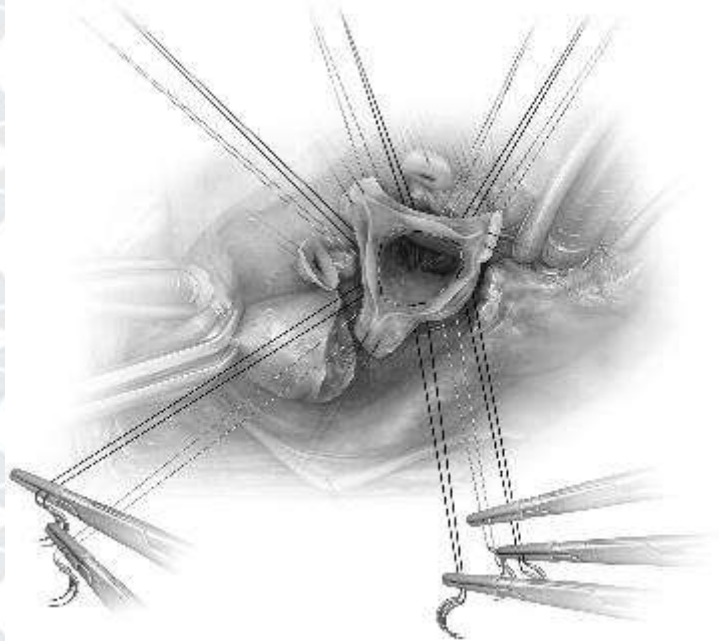
Endovascular repair of the descending aorta



Valve Sparing Root Replacement

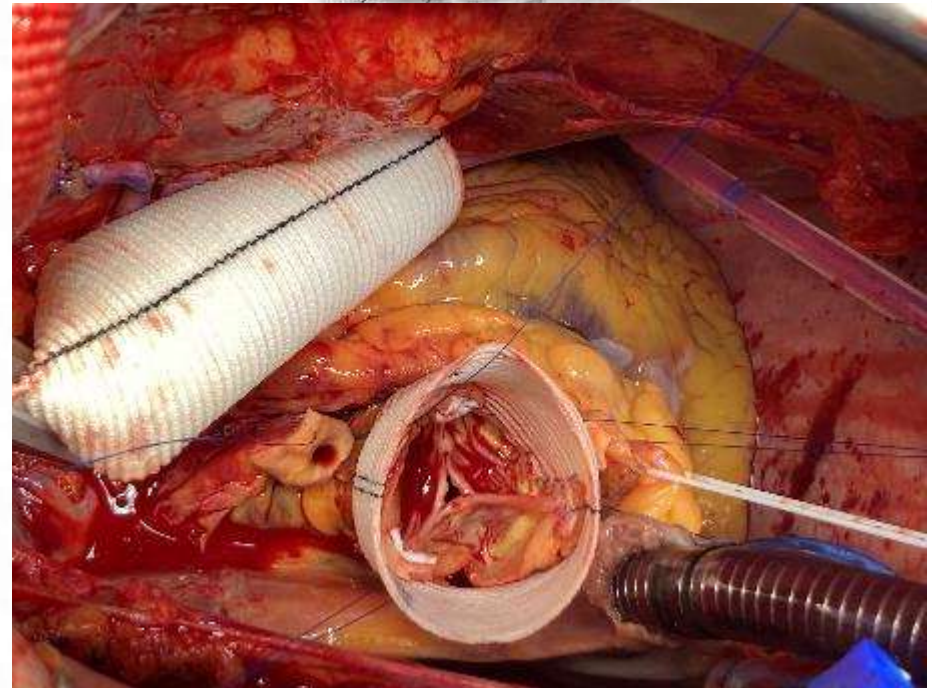

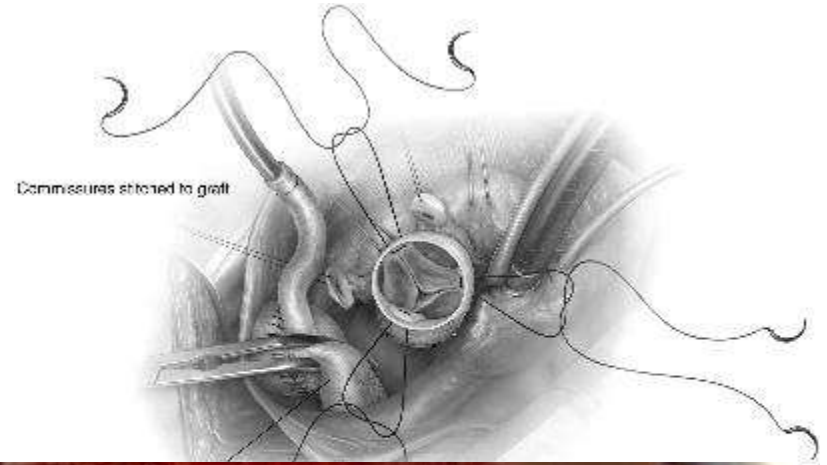
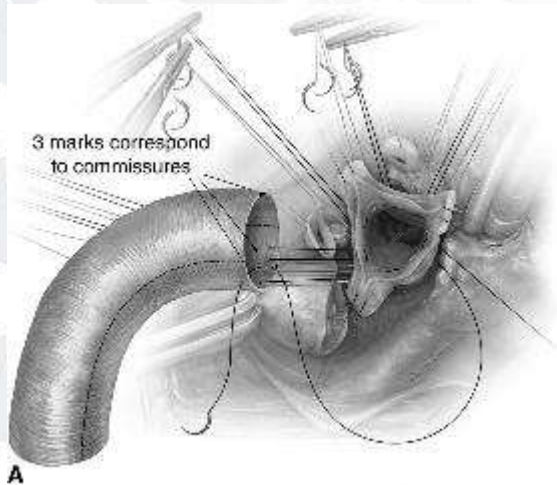


A

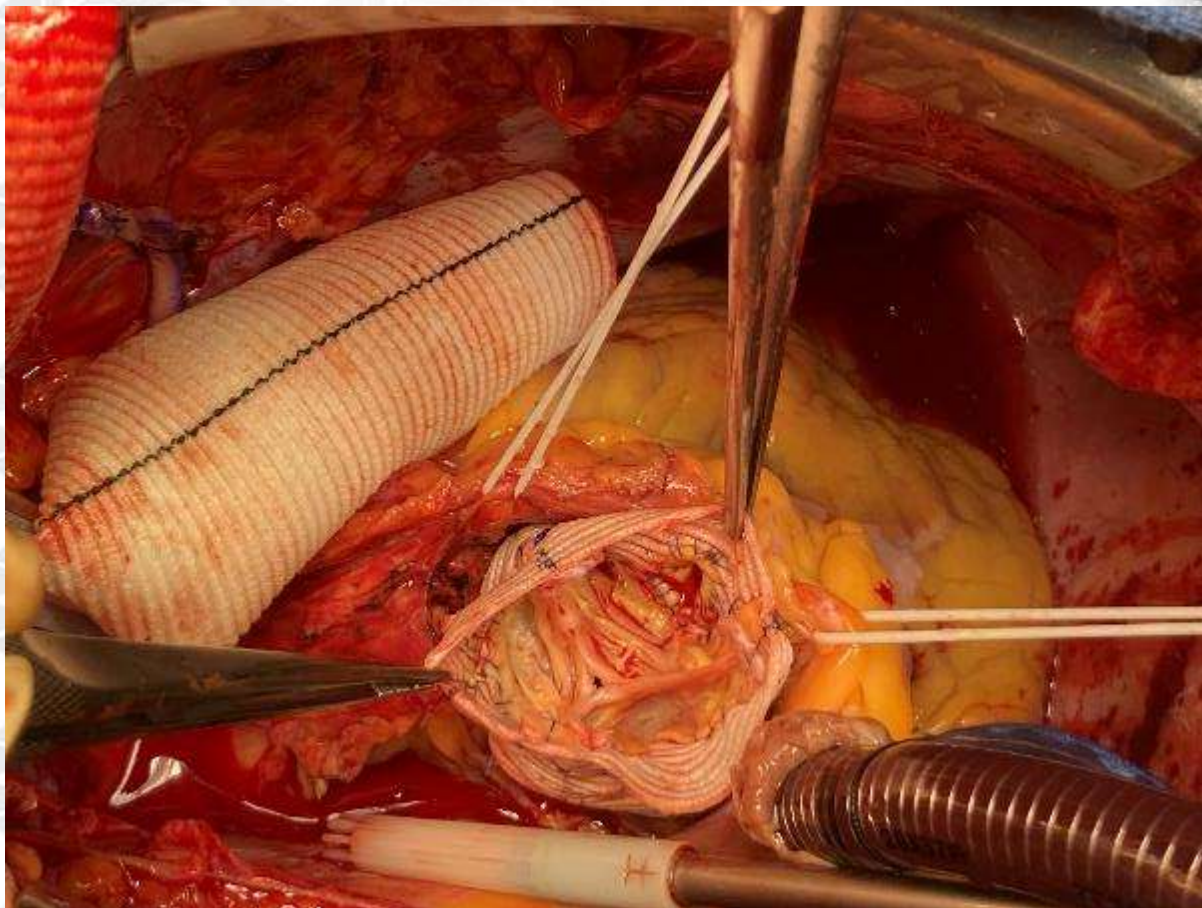
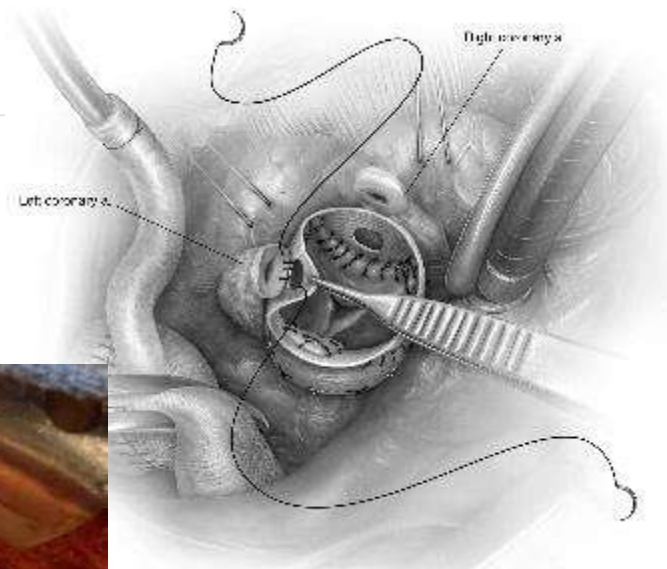


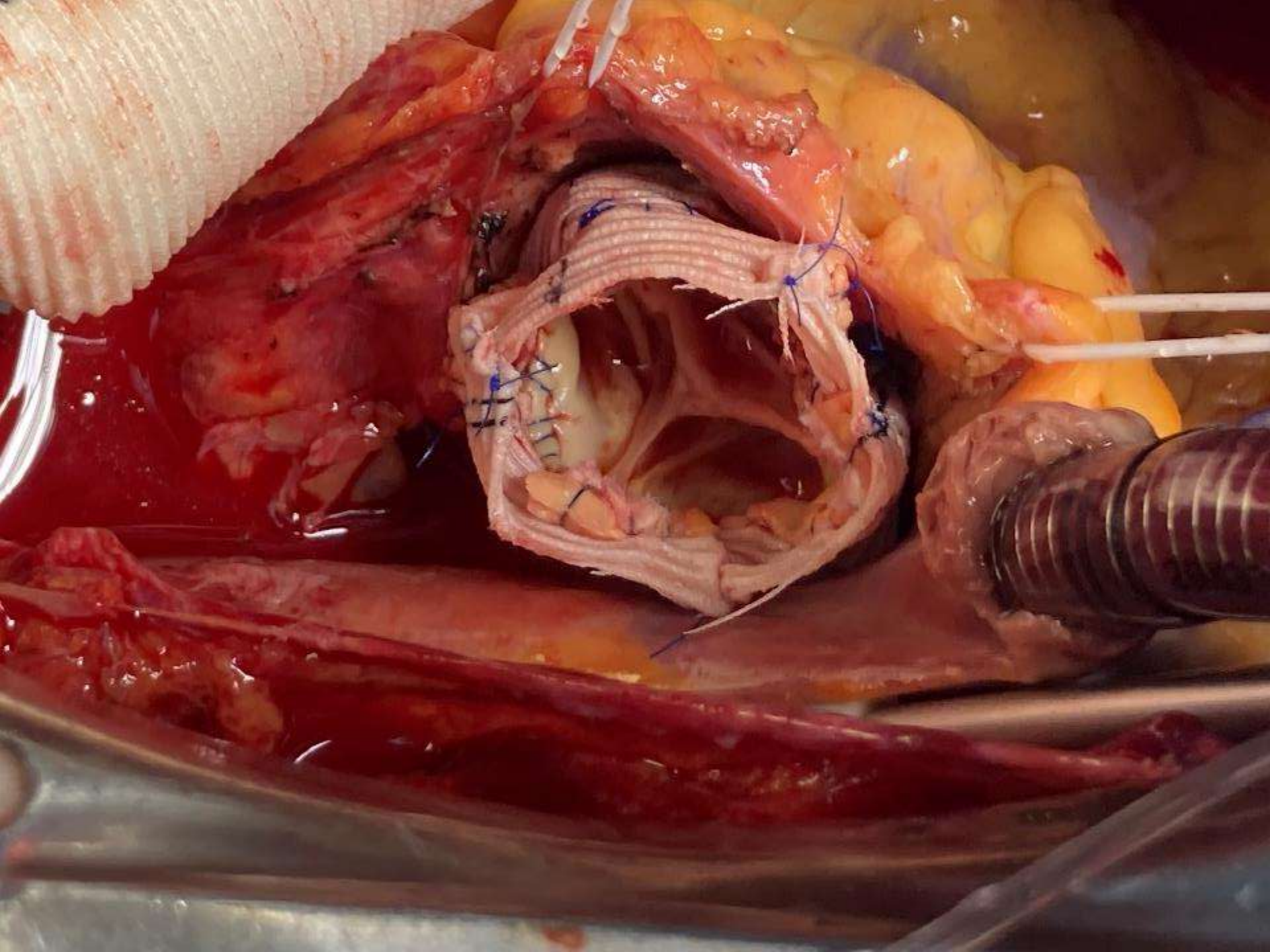
B

Valve Sparing Root Replacement

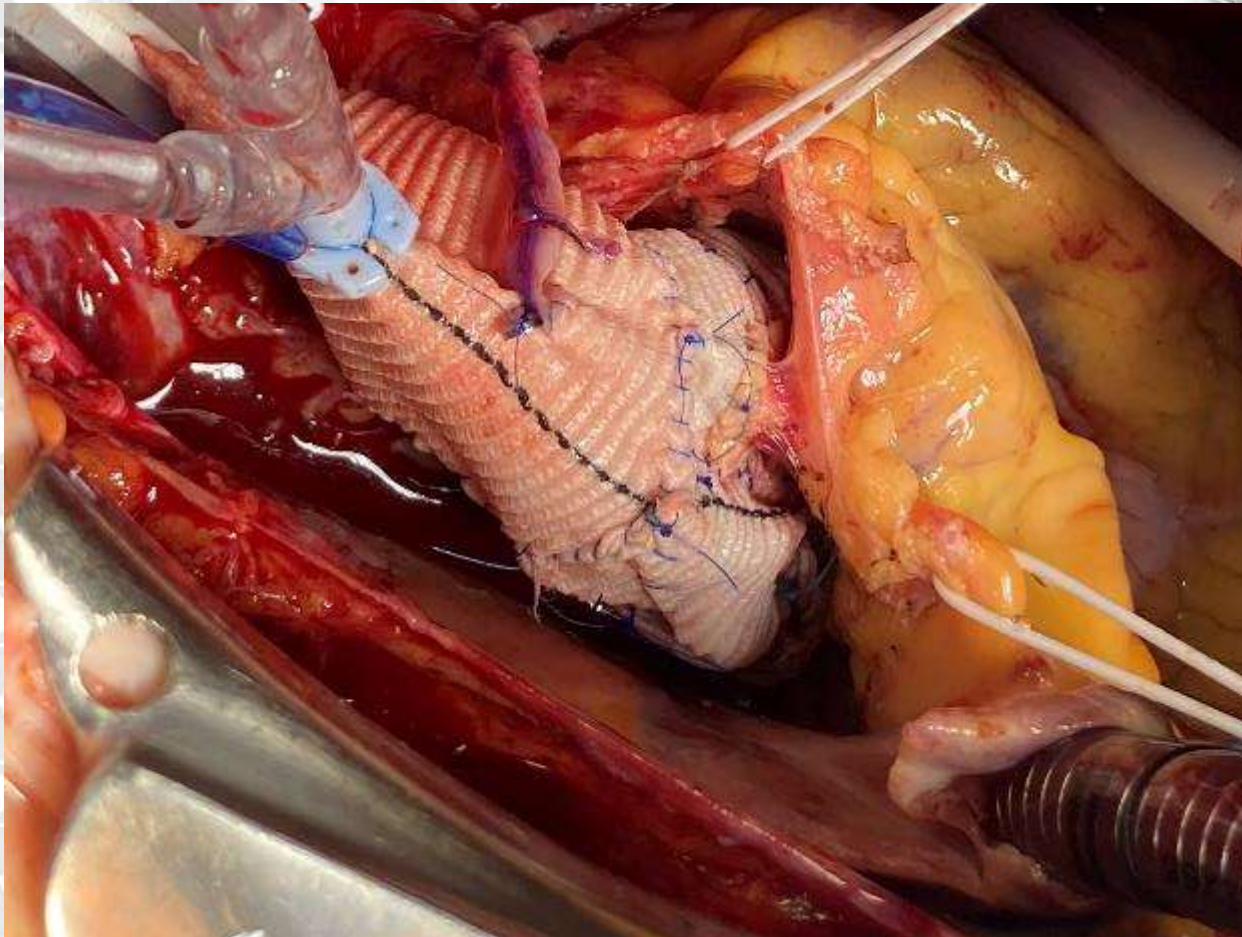
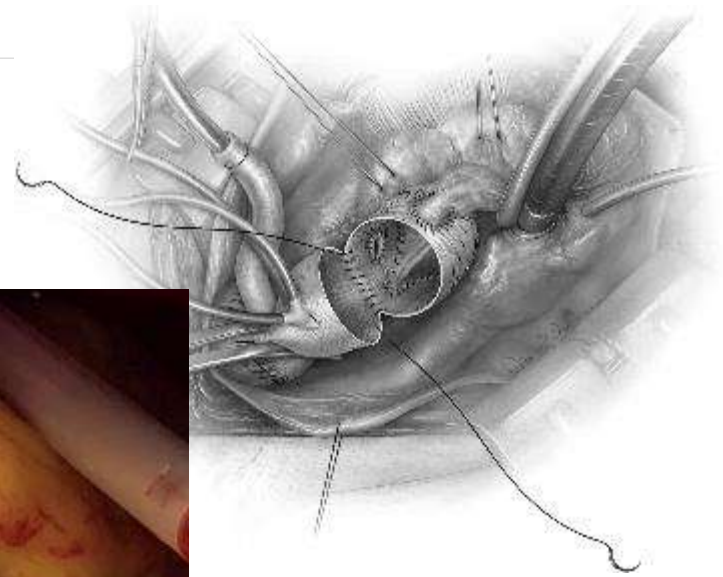


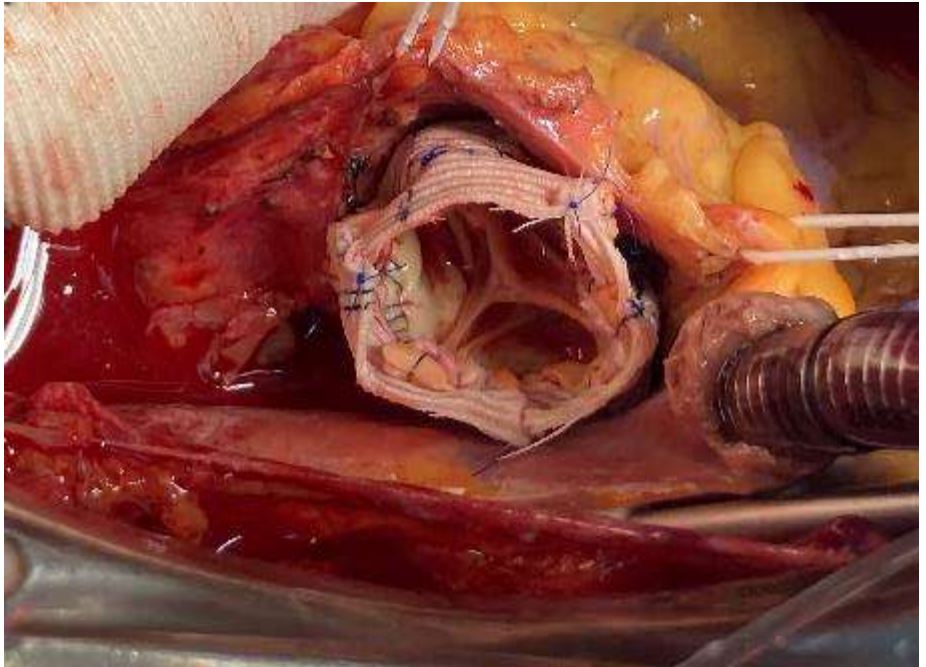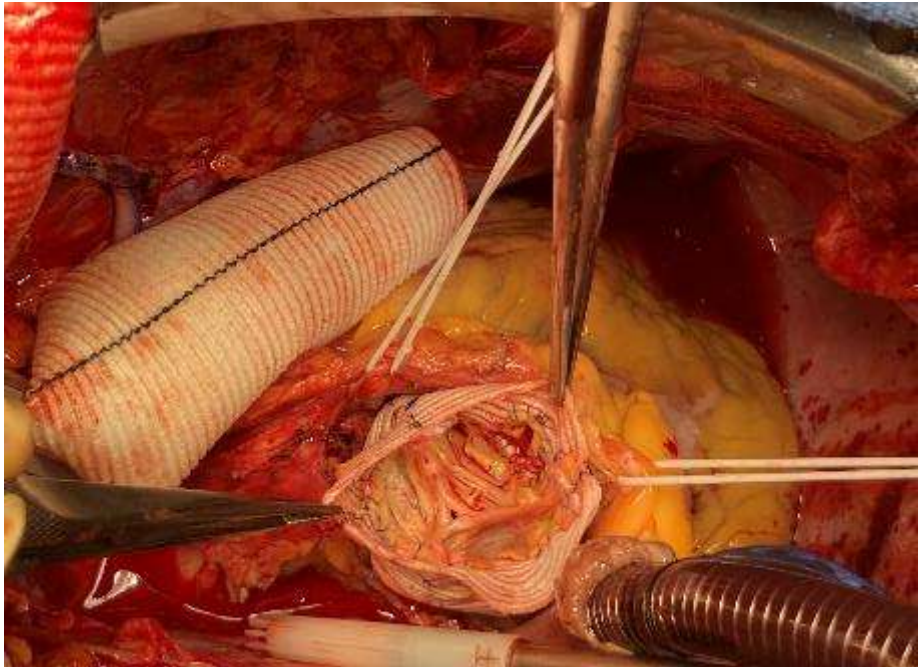
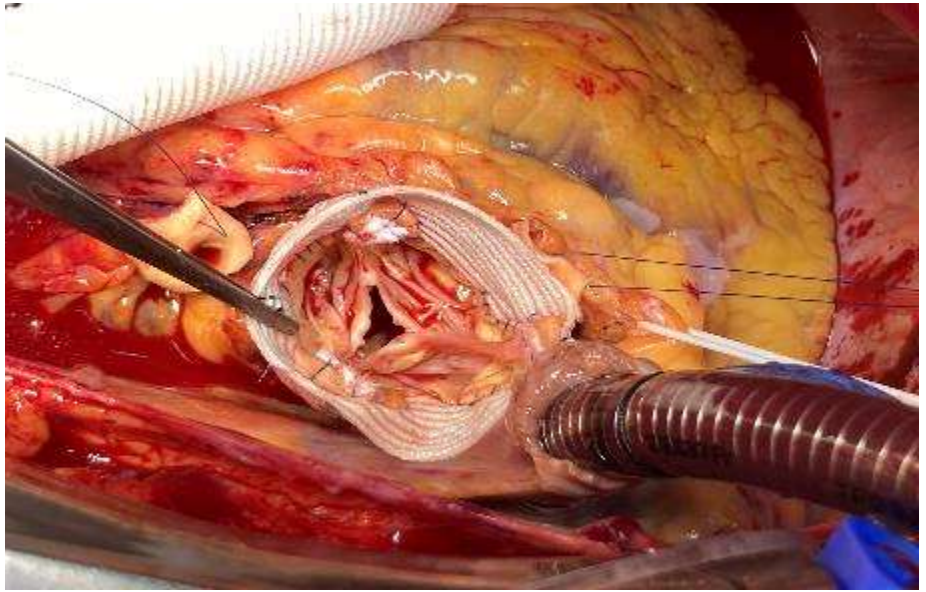
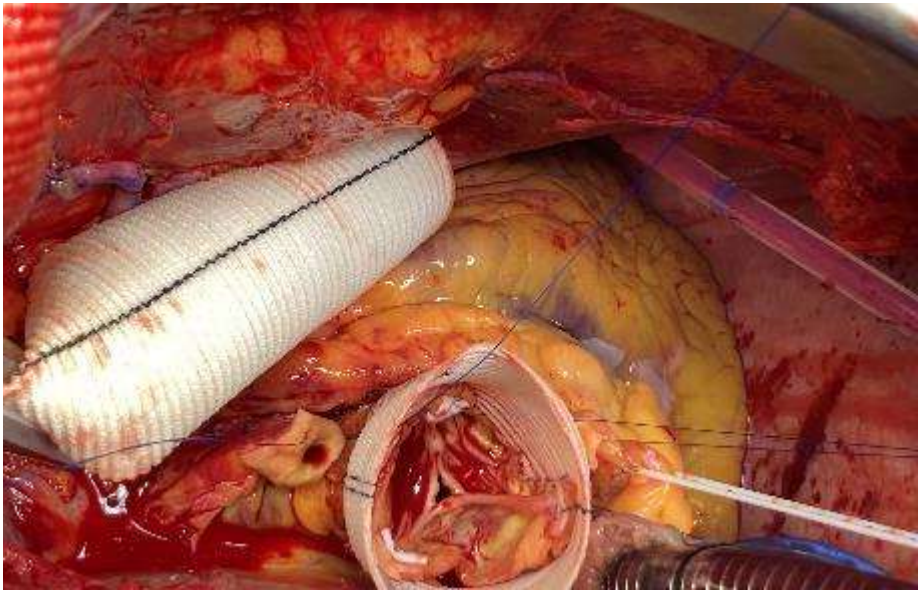
Valve Sparing Root Replacement





Valve Sparing Root Replacement





PHILIPS

TIS0.7 MI 0.4

X7-2t/TEE

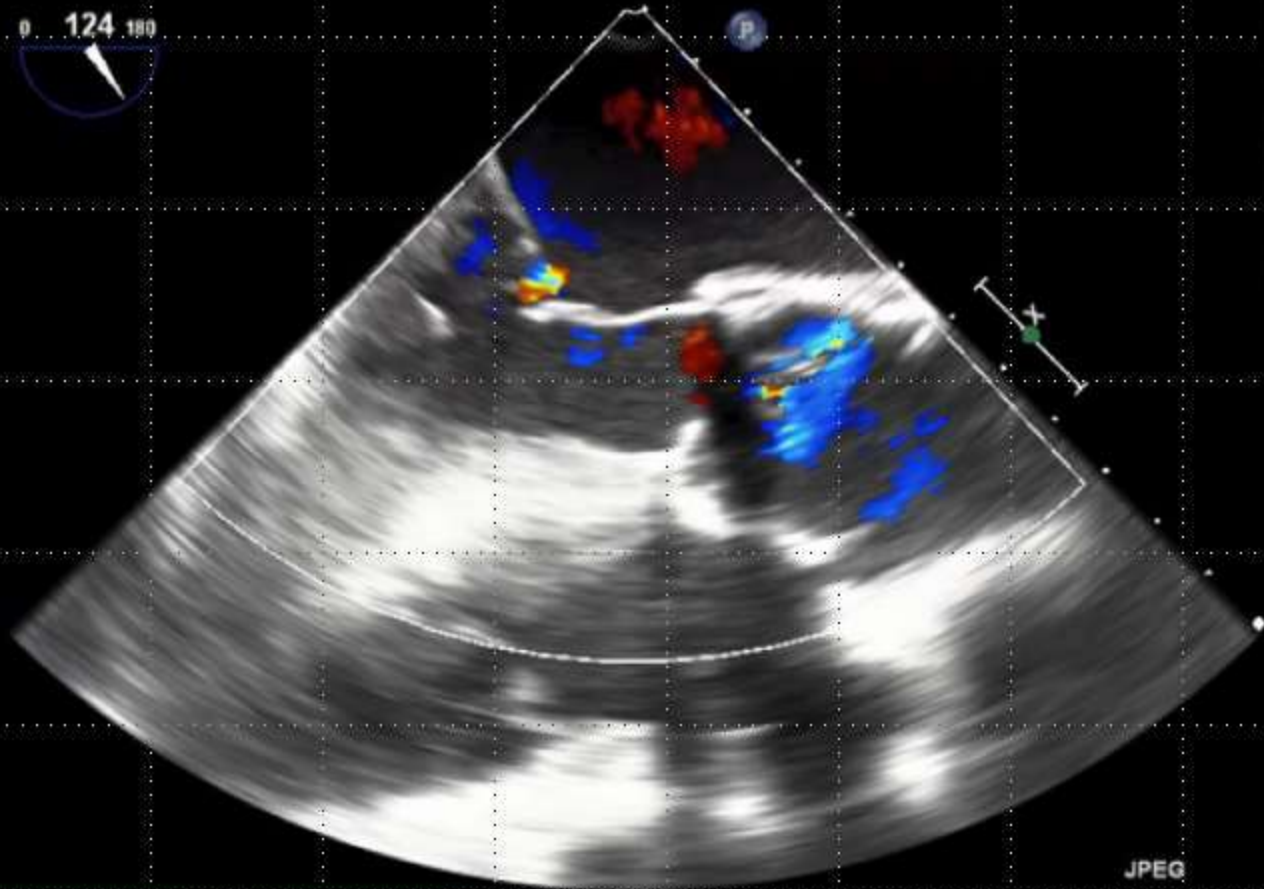FR 11Hz
12cm

2D
76%
C 52
P Off
Gen



CF
57%
4.4MHz
WF High
Med

M4 M4
+61.6

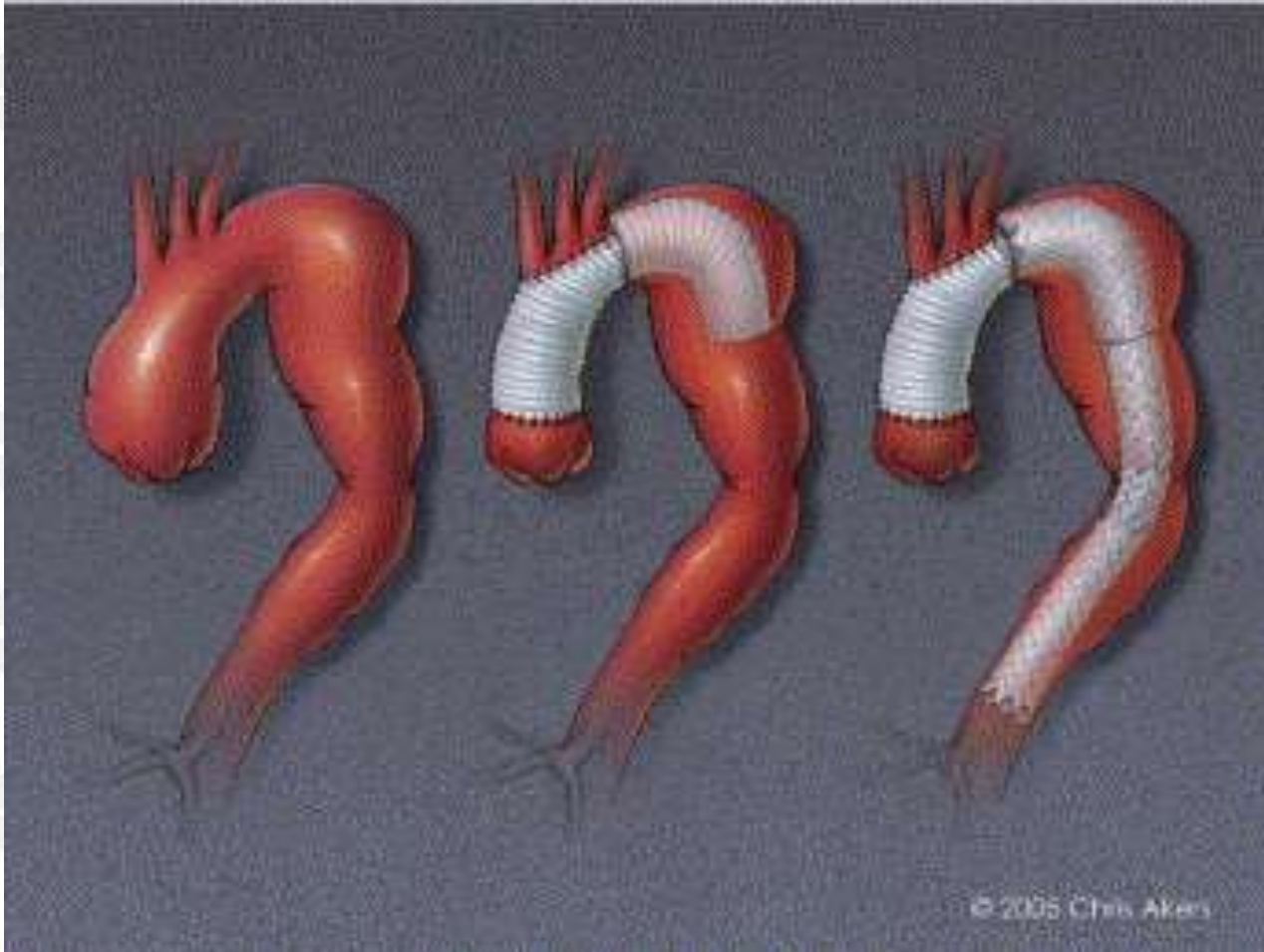


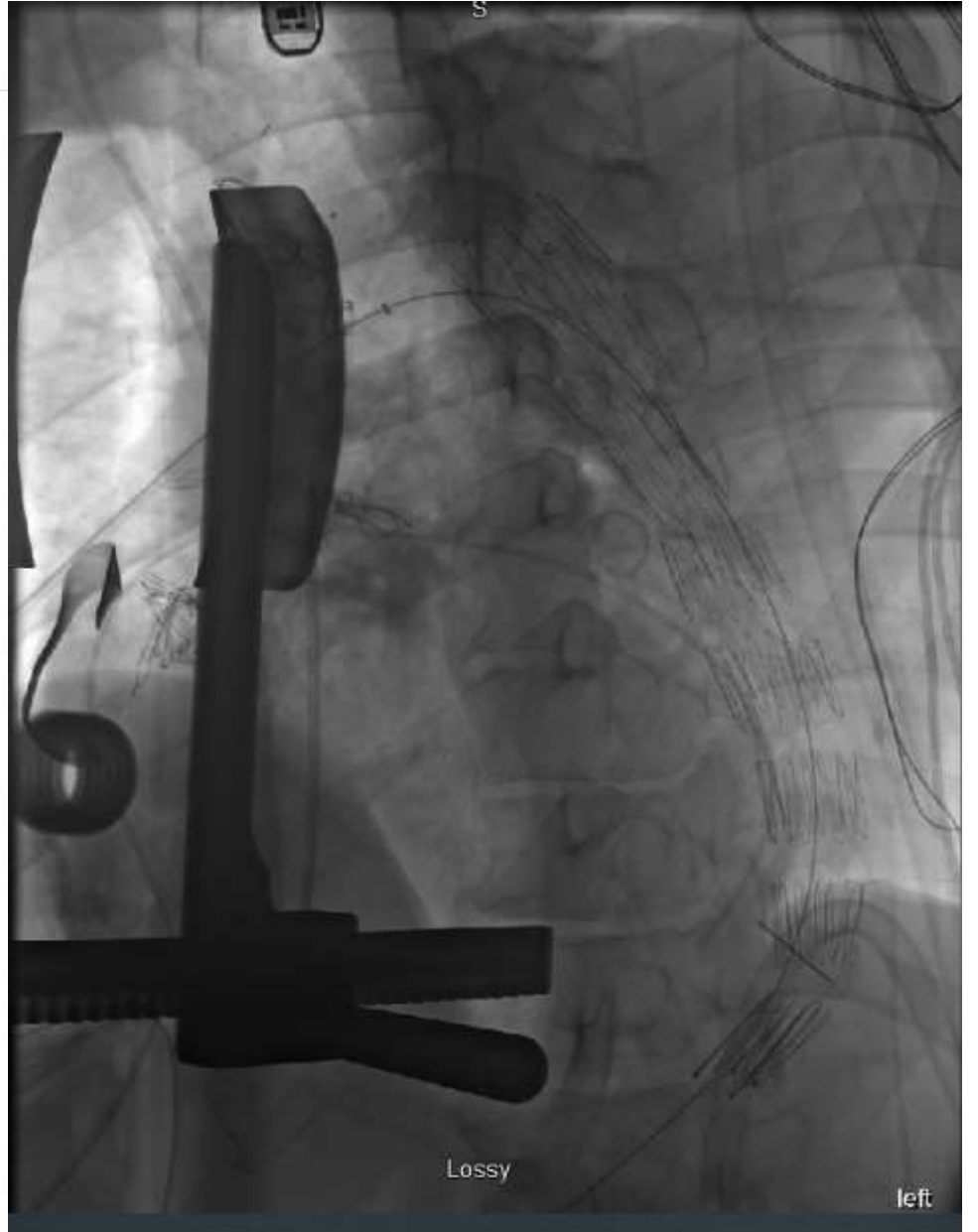
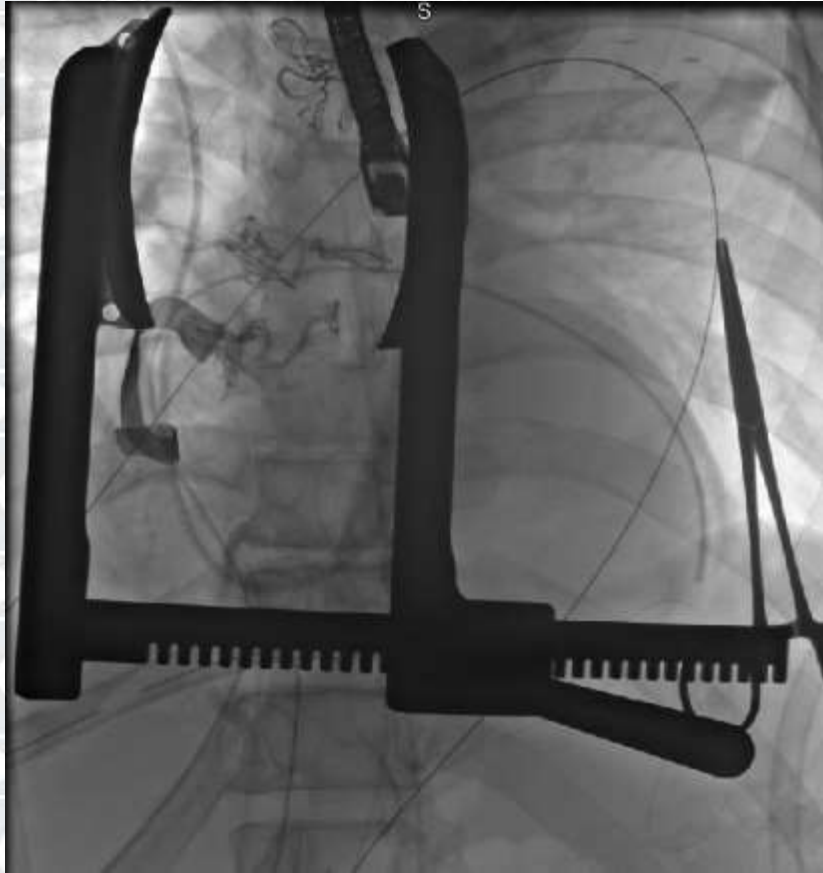
JPEG


PAT T: 37.0C
TEE T: 38.3C

*** bpm

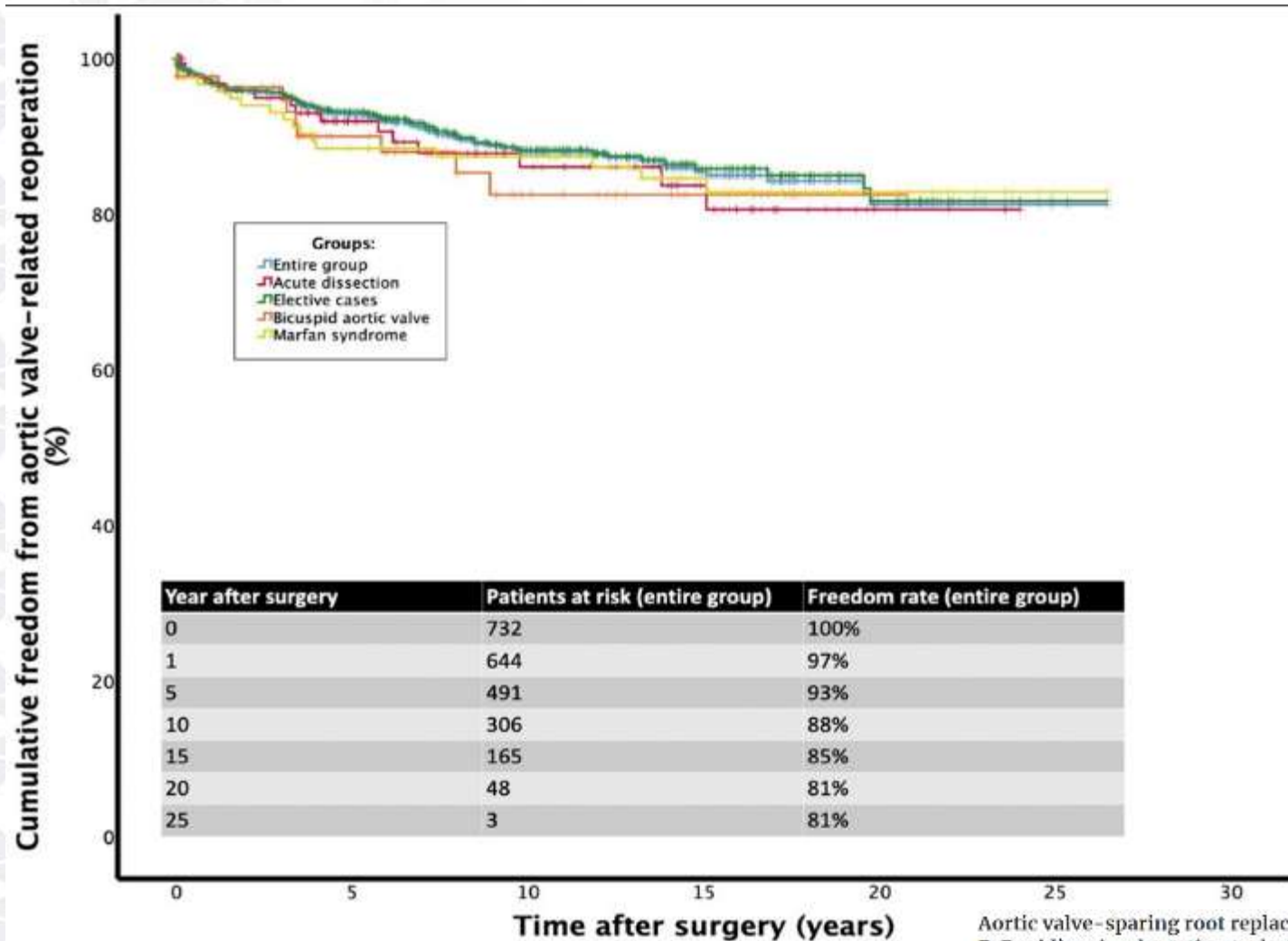
Arch replacement and elephant trunk







Freedom from reoperation



Aortic valve-sparing root replacement with Tirone E. David's reimplantation technique: single-centre 25-year experience

Link Deckmann, Andrew Mattens, Heike Krüger, Wilhelm Korte, Tim Kaufeld, Alissa Stettinger, Axel Haverich, Malakh Lal Shrestha

European Journal of Cardio-Thoracic Surgery, Volume 60, Issue 3, September 2021, Pages

642-648, <https://doi.org/10.1093/ejcts/ezab136>

Published: 29 March 2021 Article history



Thoracic aortic surgery at Roper

Indications for surgery

-Symptoms

-Size

-Rate of change

-Aortic insufficiency

Aortic surgical size criteria

Ascending aorta

55 mm standard

Adjust for body size

$$BSA \times 2.75 = SSC$$

Adjust for risk factors

connective tissue disorders

Varies by disease

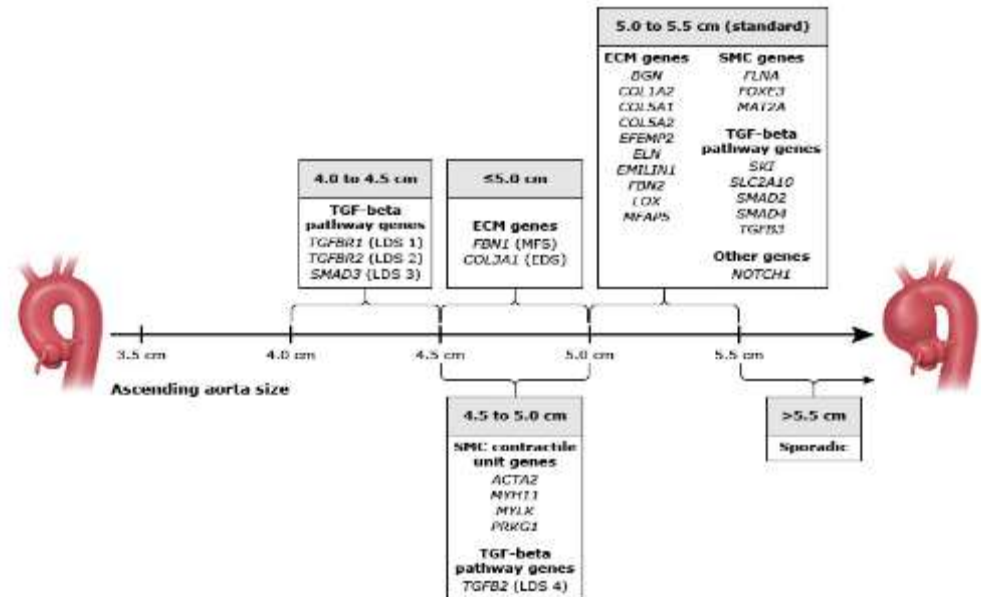
Personal or family history

Subtract 5 mm or

$$BSA \times 2.5 = SSC$$

BSA	Aortic size (cm)									
	3.5	4.0	4.5	5.0	5.5	6.0	6.5	7.0	7.5	8.0
1.30	2.69	3.00	3.46	3.85	4.23	4.62	5.00	5.38	5.77	6.15
1.40	2.50	2.86	3.21	3.57	3.93	4.29	4.64	5.00	5.36	5.71
1.50	2.33	2.67	3.00	3.33	3.67	4.00	4.33	4.67	5.00	5.33
1.60	2.19	2.50	2.80	3.13	3.44	3.75	4.06	4.38	4.69	5.00
1.70	2.05	2.35	2.65	2.94	3.24	3.53	3.82	4.12	4.41	4.71
1.80	1.94	2.22	2.50	2.78	3.06	3.33	3.61	3.89	4.17	4.44
1.90	1.84	2.11	2.37	2.63	2.89	3.16	3.42	3.68	3.95	4.22
2.00	1.75	2.00	2.25	2.50	2.75	3.00	3.25	3.50	3.75	4.00
2.10	1.67	1.90	2.14	2.38	2.62	2.86	3.10	3.33	3.57	3.80
2.20	1.59	1.82	2.05	2.27	2.50	2.72	2.95	3.18	3.41	2.64
2.30	1.52	1.74	1.96	2.17	2.39	2.61	2.83	3.04	3.26	3.48
2.40	1.46	1.67	1.88	2.08	2.29	2.50	2.71	2.92	3.13	3.33
2.50	1.40	1.60	1.80	2.00	2.20	2.40	2.60	2.80	3.00	3.20

- = low risk (~4% per yr)
- = moderate risk (~8% per yr)
- = severe risk (~20% per yr)



Roper Thoracic Aortic Clinic

Purpose:

- grow volume
- increase efficiency

State of the art care

- Guideline driven
- Medical optimization focused on prevention and disease progression
- Surgical expertise
- Genetic testing and counseling
- Personalized approach
 - risk factors
 - body size

Roper Thoracic Aortic Clinic

Roper thoracic aortic clinic volume

Year	New	Follow up	Total
2019	65	39	104
2020	76	58	134
2021	127	79	206

Roper thoracic aortic surgical volume

	Isolated Aortic (elective)	Aortic + Additional Procedure	Emergent Aortic Procedures	All Aortic Procedures
2017	13	12	6	31
2018	15	5	9	29
2019	19	9	9	37
2020	23	9	7	39

Roper thoracic aortic surgical quality

	Isolated Aortic (elective)	Stroke (N)	Mortality (N)	Absence of Stroke or Mortality (N)	Absence of Stroke or Mortality (%)
2017	13	0	0	13	100%
2018	15	0	0	15	100%
2019	19	0	1	18	95%
2020	23	1	0	22	96%
2017-2020	70	1	1	68	97%

Thoracic aortic disease

Take home messages

- Valve sparing root is an attractive option in select patients
- VSR is a durable technique that combines the longevity of mechanical valve conduit and freedom from bleeding and thromboembolism of a bioprosthetic valve conduit.
- Aortic surgery requires a multidisciplinary approach
- Endovascular options for the descending thoracic aorta can be facilitated or enhanced by open ascending aortic procedures

Questions?